

Extended Medial Hemisoleus Flap for Distally Extended Gustilo IIIB Middle Third Leg Compound Fractures

AHMED T. NASSAR, M.D. and SHERIF M. ELKASHTY, M.D.

The Department of Plastic and Reconstructive Surgery, Faculty of Medicine, Menoufia University, Menoufia, Egypt

ABSTRACT

Background: Multiple flaps were described for reconstruction of middle third defects. Extension of middle third defects to include the proximal part of distal third of the leg makes reconstruction more challenging. Extended hemisoleus flap allows a reliable option for reconstruction of these defects.

Aim of the Study: To assess the outcome of using extended medial hemisoleus muscle flap to reconstruct distally extended middle third leg defects.

Patients and Methods: The study included 9 patients with Gustilo (III) middle third leg defects that extended to adjacent upper part of the distal third. Extended medial hemisoleus muscle flap was used to manage these defects accompanied with immediate or delayed split thickness skin graft. Assessment of the outcome of this flap was done.

Results: Partial flap loss occurred in 1 patient (11.1%). No functional deficit was detected. Aesthetic outcome was good and satisfactory to the patients including color of the flap with the covering graft and the scar in 8 patients (88.9%).

Conclusion: The extended hemisoleus muscle flap can be used as a reliable flap for coverage of the tibial wounds with exposed bone at the junction of middle and distal third.

Key Words: *Extended hemisoleus flap – Distal middle leg defects – Muscle flaps.*

INTRODUCTION

Open tibial fracture (usually Gustilo IIIB) is most commonly located in the junction of the middle and distal thirds of the leg because of the unique anatomic features in the region. Very often, these tibial wounds appear to be relatively too small for free tissue transfer but clearly too large for primary wound closure [1].

The Gustilo classification for open fractures is a well-recognized system of categorizing com-

pound extremity fractures based on severity of trauma, defect size, contamination, soft tissue loss, and vascular injury. Grade IIIB fractures have open wounds greater than 10cm in size, with severe soft-tissue loss but no vascular injury requiring repair. These fractures are grossly displaced and contaminated, and may include segmental bone loss [2-4].

The remaining soft tissue is inadequate for wound closure, so regional and/or distant flaps are required for coverage. Therefore, these complicated injuries have both soft-tissue and bony elements that need appropriate therapy for successful healing and eventual limb salvage. The basic principles for treating grade IIIB fractures include meticulous serial debridement and removal of all necrotic bone, followed by rigid fixation and healthy, well-vascularized soft-tissue coverage [5].

The use of a hemisoleus muscle flap was first advocated by Tobin in 1985 [6]. However, the reliability and usefulness of a medial hemisoleus muscle flap for soft-tissue coverage of a relatively distal tibial wound have not been confirmed. Furthermore, use of the flap to reconstruct an open tibial wound in the junction of the middle and distal thirds of the leg has not been reported [1].

PATIENTS AND METHODS

This study was done at The Department of Plastic and Reconstructive Surgery, Menoufia University Hospitals, between December, 2013 and January, 2015 with a follow-up period of average of 12 months. It included nine patients who had Gustilo IIIB compound fractures of the leg. The site of the lesion was extending between

distal part of the middle third of the leg and proximal part of distal third or large middle third defects that distally extend to the proximal part of the distal third. The age of the patients ranged between 9 yrs to 50 yrs with mean age (29.9 ± 11.6 yrs). All patients were males. Motor cycle accident was the cause of trauma in 4 patients, car accident was the cause in other 3 patients, Toktok caused the trauma in one patient and one patient with resistant osteomyelitis. Trauma was at the right leg in 6 patients and at the left leg in 3 patients. Immediate coverage was done in one patient while early coverage was done in one patient 3 days after trauma. Late coverage which was done after 2 weeks of trauma was done in 7 patients. External fixation, frequent surgical debridement, dressing and wound care were done in those cases where the wound was contaminated till the wound condition allowed late flap coverage. External fixation and wound dressing were done at time of trauma followed by flap coverage in case where early coverage was used. The patient who was managed immediately, the trauma caused by train and he was the youngest (9 years) old with degloving injury of the leg. Immediate split thickness skin graft (STSG) was done in 7 patients while late STSG was used in 2 patients. Suction drain was inserted in donor site in all patients. Spinal anesthesia was used in 7 patients and general anesthesia in 2 patients.

Surgical technique:

All the procedures were done under general or spinal anesthesia, with tourniquet control and loupe magnification. Tibial fractures fixed by external fixators, and aggressive debridement of osteomyelitis were done by orthopedic surgeons. The soleus muscle was exposed by an incision 2 finger breadth behind the medial border of the tibia that was connected to the already present defect. The soleus muscle was dissected from the gastrocnemius muscle posteriorly by blunt dissection. The medial origin of the soleus from the tibia was detached by diathermy. The plane between the soleus muscle and the flexor digitorum longus anteriorly, was entered carefully, where the perforators from the posterior tibial vessels to the medial soleus head were encountered. The lower most perforators were ligated and the medial head was separated from the lateral head along the intermuscular raphe, from distal to proximal, until the freed muscle flap seemed sufficient to cover the defect. The tourniquet was deflated, hemostasis was done, and flap viability was checked. The dissected medial hemisoleus muscle was sutured to the defect and

suction drain was inserted in the donor site. The muscle flap was skin-grafted either primarily or secondarily.

RESULTS

The study included 9 patients; all were males, with age ranging from 9-50 years. All patients had defects in the zone between middle and lower third of the tibia due to road traffic accidents. The defects were Gustilo IIIB. The defects longest dimensions were ranging from 4 to 20cm with exposed bones ranging from 4 to 16cm. There was bone loss in two cases.

The right leg was injured in 6 cases while left leg was involved in 3 cases. Reconstruction was done immediately in 1 case while the other 8 cases were reconstructed within 7 to 21 days after trauma.

General anesthesia was used in 2 patients while spinal anesthesia was used in remaining 7 patients. Suction drain was used in all cases at the donor site. Immediate skin grafting of the flap was done in 7 patients. Late grafting of the flap was done for the remaining two cases within the first week after doing the flap. Pre operative antibiotic (third generation cephalosporin) was used at the start of the procedure.

Flap exposure was done two days post operatively, when the skin graft was not done immediately. In case of doing immediate skin grafting of the flap, exposure was done after 5 days post operatively. Topical amikacin spray was used for dressing and systemic antibiotic (third generation cephalosporin) injection for 5 to 7 days.

Post operative infection occurred in 3 cases, in the form of mild discharge, managed with conservative treatment. Culture showed *S. aureus* infection. Adding linezolid antibiotic was enough to control the infection. Partial flap loss of the distal 3cm of the flap occurred in one case and it was managed by frequent dressing which was enough with no residual bone exposure.

Aesthetic outcome was assessed after 3 months including assessment of skin color, texture, shape of the scar both in donor and recipient sites, leg contour and patient satisfaction. It was good outcome in 8 patients (88%). Functional outcome was good with no defect in planter flexion and leg movement, Figs. (1,2,3) and Tables (1,2,3).

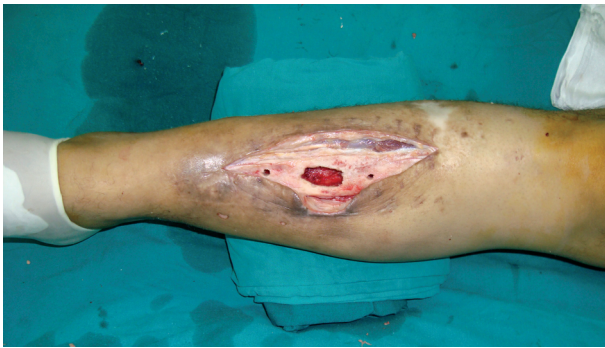

Fig. (1-A): Exposed tibia after drilling and debridement.

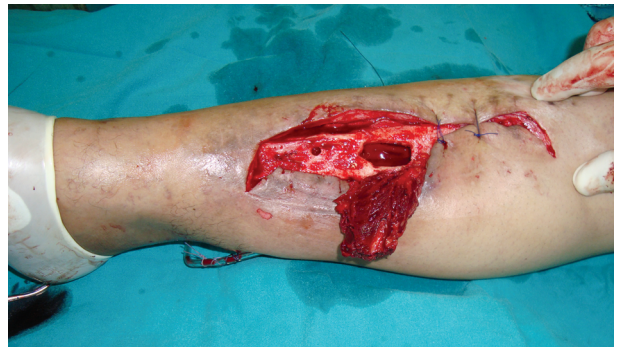


Fig. (1-B): Hemisoleus muscle flap elevated.

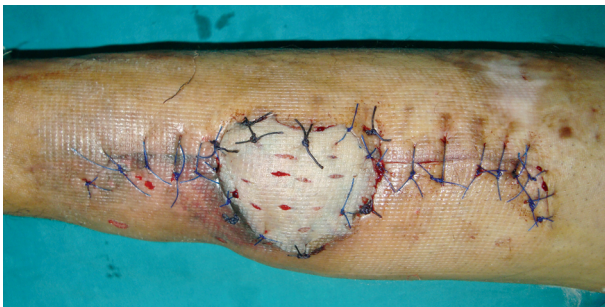

Fig. (1-C): Immediate coverage of the flap with skin graft.

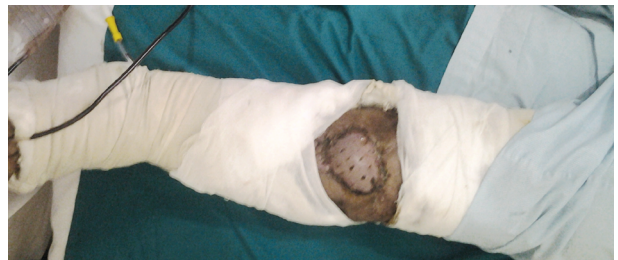

Fig. (1-D): Post operative follow-up of the flap after two weeks.

Fig. (1): Male patient 35 yrs old, with junctional middle and distal third tibial fracture followed by osteomyelitis.

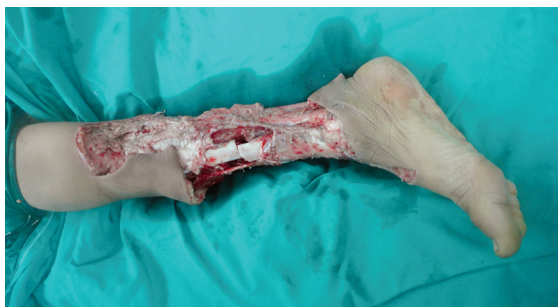

Fig. (2-A): Pre operative lateral view shows exposed bone and fracture with skin and soft tissue loss.

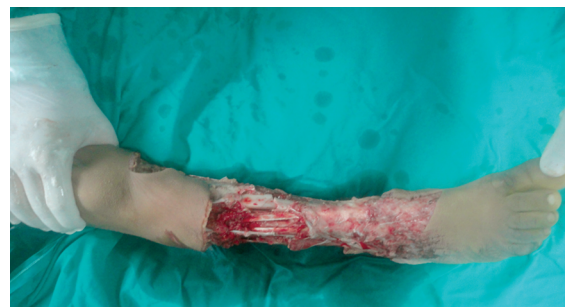

Fig. (2-B): Pre operative frontal view of the previous patient.

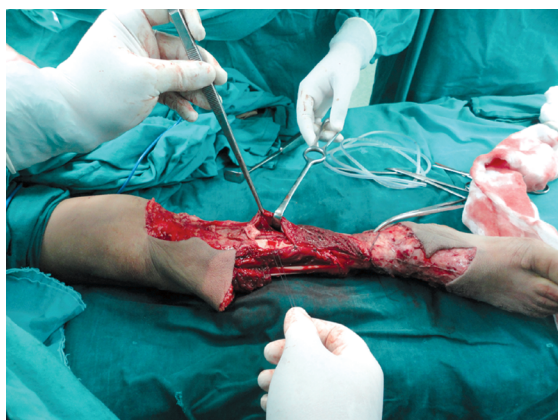

Fig. (2-C): Elevated hemisoleus muscle flap in place with preservation of posterior tibial artery perforator to the muscle.

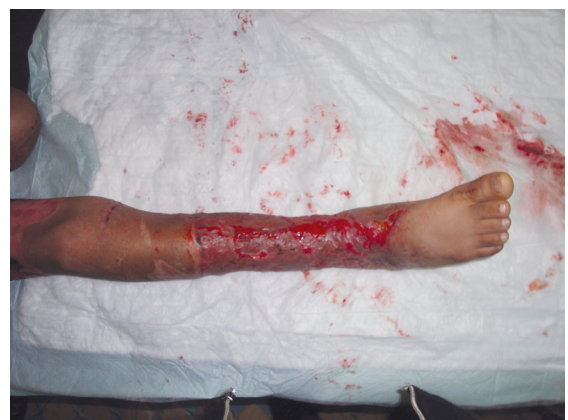

Fig. (2-D): Post operative photo one month later after split thickness graft and follow-up.

Fig. (2): A boy 9 yrs old with compound right leg fracture and degloved skin. Exposed tibial fracture and exposed bone involving middle and distal third of right tibia.

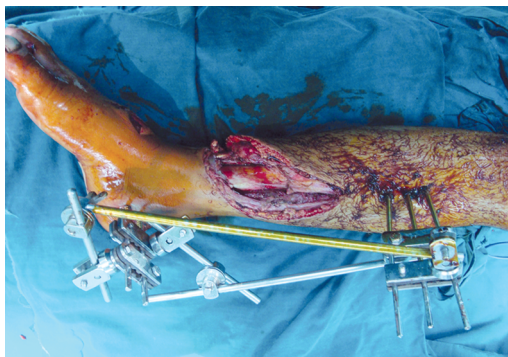

Fig. (3-A): Preoperative photo show the fracture and soft tissue loss.

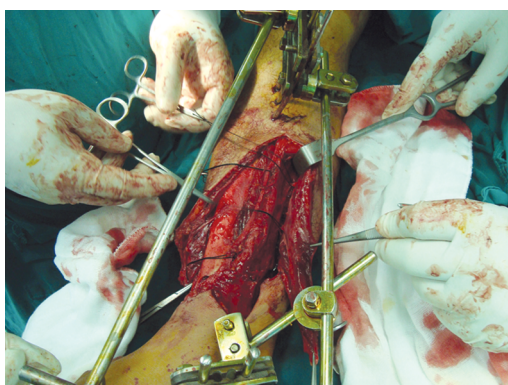


Fig. (3-B): Elevated hemisoleus muscle with marked and preserved posterior tibial feeding perforators to the muscle.

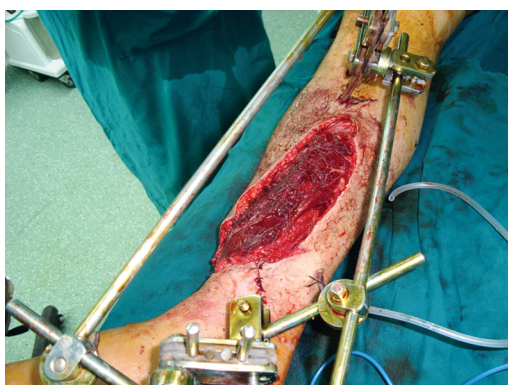

Fig. (3-C): Muscle flap cover the fracture and replace soft tissue defect.

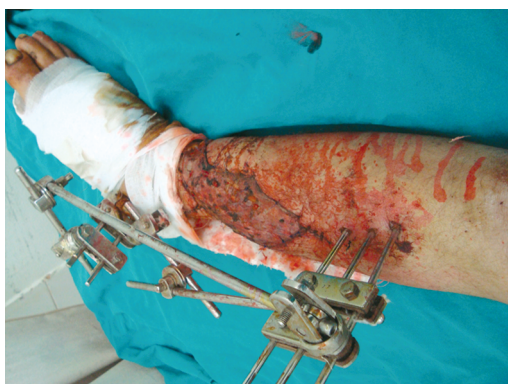

Fig. (3-D): Two-weeks post operative after immediate split thickness graft of the muscle flap.

Fig. (3): Male 29 yrs old with compound fracture at junction between middle and distal third of tibia.

Table (1): Baseline characteristics of the studied patients.

		The studied cases N = 9	
		No.	%
<i>Age:</i>	X ± SD	29.9±11.6 yrs.	
	Range	9-50 yrs.	
<i>Defect (longest dimension):</i>	X ± SD	14.6±6.0 cm.	
	Range	4-20 cm.	
<i>Defect (area):</i>	X ± SD	141.0±97.4 cm ²	
	Range	16-300 cm ²	
<i>Exposed bone (longest dimension):</i>	X ± SD	9.0±3.5 cm.	
	Range	4-15 cm.	
<i>Exposed bone (area):</i>	X ± SD	35.2±18.2 cm ²	
	Range	12-67.5 cm ²	
<i>Sex:</i>	Male	9	100
	<i>Cause:</i>	Traffic accident	9
<i>Side:</i>	Rt leg	6	66.7
	Lt leg	3	33.3
<i>Bone loss:</i>	Yes	2	22.2
	No	7	77.8
<i>Reconstruction time:</i>	Immediate	1	11.1
	Late	8	88.9
<i>Preoperative antibiotics:</i>	Yes	7	77.8
	No	2	22.2

Table (2): Operative data of the studied patients.

		The studied cases N = 9	
		No.	%
<i>Anesthesia:</i>	General	2	22.2
	Spinal	7	77.8
<i>Intra operative antibiotics:</i>	Yes	9	100
	<i>Graft:</i>	Immediate	7
Late		2	22.2
<i>Drain donor:</i>	Yes	9	100
	<i>Exposure post:</i>	2 days	2
3 days		5	55.6
5 days		2	22.2
<i>Dressing:</i>	Amikacin	9	100

Table (3): Post operative results of the studied patients.

	The studied cases N = 9	
<i>Hospital stay/days:</i>		
X ± SD	7.8±8.5	
Range	1-21	
	No.	%
<i>Infection:</i>		
Yes	3	33.3
No	6	66.7
<i>Partial flap loss:</i>		
Yes	1	11.1
No	8	88.9
<i>Functional outcome:</i>		
Normal	9	100
<i>Aesthetic outcome:</i>		
Good	8	88.9
Moderate	1	11.1

DISCUSSION

In this study, 9 patients were included; all were males, with age ranging from 9-50 years. Motor-cycle accident was the cause of trauma in 4 patients, car accident was the cause in other 3 patients, Toktok caused the trauma in one patient and one patient with resistant osteomyelitis. Trauma was at the right leg in 6 patients and at the left leg in 3 patients. The longest dimension of exposed tibial bone ranged from (4 to 16cm).

In a study done by Lee in 2006 for 2 years, 14 patients (11 males and 3 females; age range 23-61 years) were included. The causes of their lower extremity soft-tissue wounds were motor vehicle accident in 10 patients, fall in 1 patient, and post-surgical debridement for infection in 3 patients. The location of soft-tissue wounds were on the right side in 8 patients and on the left side in 6 patients. The longest dimensions of the exposed tibial bone were (4 to 10cm), in the junction of the middle and distal thirds of the leg [1].

Joel et al., had their study performed over 2-year period and included 28 patients who required flap coverage of defects of the lower third of the leg. In their study, the soleus muscle was used successfully in all patients, with no clear data concerning size of the defect or the patient criteria [7].

Post operative infection in this study occurred in 3 patients (33.3%). Partial flap loss occurred in 1 patient (11.1%). No functional deficit was detected. Aesthetic outcome was good and satisfactory to the patients including color of the flap with the covering graft and scar in 8 patients (88.9%).

In Lee study, thirteen patients had primary healing of their tibial wounds without any complications. Only 1 patient (7.1%) developed insignificant distal flap necrosis and was treated subsequently with surgical debridement and flap readvancement. All patients (100%) had reliable healing of their tibial wounds and evidenced healing of their fractures, with good cosmetic outcome following flap reconstructions [1]. While in Joel et al., study; All of the soleus flaps survived, and all these patients' wounds went on to heal completely [7].

Conclusion:

Hemisoletus flap can be used as a reliable flap for coverage of the tibial wounds with exposed bone at the junction of middle and distal third of the leg with longest dimensions up to 14cm with good functional outcome and bone coverage. The aesthetic outcome was satisfactory for patients in regard to skin color matching and shape of the scar.

REFERENCES

- 1- Lee L.Q. Pu: Tissue Coverage of an Open Tibial Wound in the Junction of the Middle and Distal Thirds of the Leg with the Medial Hemisoletus Muscle Flap. *Ann. of Plast. Surg.*, 56 (6): 639-643, 2006.
- 2- Gustilo R.B., Simpson L., Nixon R., et al.: Analysis of 511 open fractures. *Clin. Orthop.*, 66: 148, 1969.
- 3- Gustilo R.B., Mendoza R.M. and Williams D.N.: Problems in the management of type III (severe) open fractures: A new classification of type III open fractures. *J. Trauma*, 24: 746, 1984.
- 4- Gustilo R.B., Gruniger R.P. and Davis T.: Classification of type III (severe) open fractures relative to treatment and results. *Orthopedics*, 10: 1788, 1987.
- 5- Parrett B.M., Matros E., Pribaz J.J. and Orgill D.P.: Lower extremity trauma: Trends in the management of soft-tissue reconstruction of open tibia-fibula fractures. *Plast. Reconstr. Surg.*, 117: 1315, 2006.
- 6- Tobin G.R.: Hemisoletus and reversed hemisoletus flaps. *Plast. Reconstr. Surg.*, 76: 87-96, 1985.
- 7- Joel B.B., F. Stile and W. Lineaweaver: Reconsidering the Soleus Muscle Flap for Coverage of Wounds of the Distal Third of the Leg. *Ann. of Plast. Surg.*, 50 (6): 631-635, 2003.